

Intestinal-type adenocarcinoma of the vagina: clinico-pathologic features of a common tumor with a rare localization

G. BROGGI, E. PIOMBINO, G. MAGRO, G.M. VECCHIO

Department of Medical and Surgical Sciences and Advanced Technologies, G.F. Ingrassia, Azienda Ospedaliero-Universitaria "Policlinico-Vittorio Emanuele", Anatomic Pathology Section, School of Medicine, University of Catania, Italy

Key words

Vagina • Adenocarcinoma • Intestinal-type • Differential diagnosis

Summary

Intestinal-type adenocarcinoma is a rare primary vaginal carcinoma and considerably more uncommon than metastatic lesions which represent the most frequent malignancy at this anatomic site. Among all malignant tumors, colorectal, breast and female genital tract carcinomas have the tendency to metastasize to the vagina. As morphologic and immunohistochemical features of intestinal-type adenocarcinoma occurring primarily in the vagina are not specific, clinical and radiologic information is crucial to exclude a metastatic lesion.

Introduction

Metastasis are the most common tumors arising from vagina, especially from close sites such as endometrium, ovary and cervix; however they can also arise from distant organs sites such as including colon, kidney, breast and pancreas¹. Primary vaginal carcinoma is an uncommon disease, accounting for approximately 1% of all gynecologic malignancies². Apart from rare cases of melanomas, soft tissue tumors, mixed epithelial-mesenchymal tumors and lymphomas, most of vaginal neoplasms are mainly represented by squamous cell carcinomas (66–80% of all cases), followed by adenocarcinomas (less than 10%)²⁻⁵. Based on histological features, primary vaginal adenocarcinomas can be distinguished into four subtypes: i) clear cell adenocarcinomas; ii) endometrioid-type adenocarcinomas; iii) mucinous adenocarcinomas; iv) intestinal-type adenocarcinomas. Most cases of vaginal adenocarcinomas are of clear cell or endometrioid-type, while intestinal-type adenocarcinomas are rare with only 19 cases reported in the English literature so far²⁻⁷. We report a rare case of intestinal-

Herein we present a rare case of intestinal-type adenocarcinoma from a villous adenoma, presenting as a polypoid mass in the posterior wall of vaginal introitus of 51-year-old menopausal woman. To the best of our knowledge, only 19 cases of intestinal-type adenocarcinoma of the vagina have been reported in the English literature so far. Notably the origin from a previous villous adenoma has been well documented only in a few cases.

type adenocarcinoma of the vagina, arising from a villous adenoma. The revision of the literature on the topic is provided, with emphasis on the diagnostic clues and differential diagnosis.

Materials and methods

A 51-year old menopausal woman was referred to Gynecological Clinic of our hospital with a history of vaginal discomfort and bleeding. She had two pregnancies, last one in 2001. She denied the use of oral contraceptives and hormone therapy. Her medical history for neoplastic diseases was negative. Colposcopy showed, at the level of the posterior wall of the vaginal introitus, a protruding, reddish, bleeding polypoid mass, measuring 2 cm in its greatest diameter. A wide excision of the lesion was performed. The surgical specimen was submitted for histological examination in neutral-buffered 10% formalin, dehydrated using standard techniques, embedded in paraffin, cut to 5 µm, and stained with hematoxylin and eosin (H&E). Immunohistochemical studies were per-

Correspondence

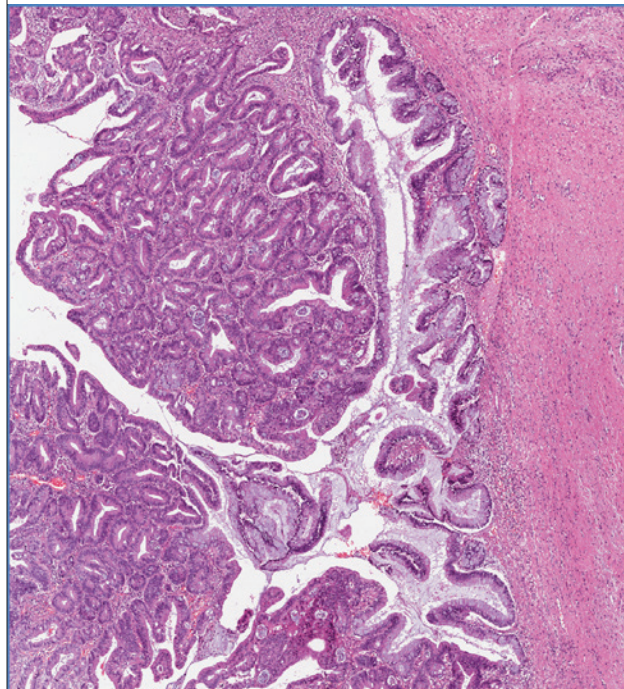
Giada Maria Vecchio, Department G.F. Ingrassia, Section of Anatomic Pathology, University of Catania, Santa Sofia 87 street, 95123 Catania, Italy - Tel. +39 095 3782022 - Fax +39 095 3782023 - E-mail: giadamariavecchio@gmail.com

formed with the labeled streptavidin–biotin peroxidase detection system; the following antibodies were tested: CDX2, CK20, CK7, CEA, p53, p16, PSA, estrogen receptors (ERs), progesterone receptors (PgRs) and p63.

Results

Gross examination of the surgical specimen showed a polypoid mass measuring cm 1.7 in its greatest diameter. Histological examination showed a moderately differentiated (G2) adenocarcinoma of the intestinal-type, infiltrating the sub-epithelial connective tissue (Fig. 1A, B). In the context of the adenocarcinoma, a small area with the characteristic features of a villous adenoma with high-grade dysplasia was identified (Fig. 2). Surgical margins were tumor-free. Immunohistochemical evaluation showed a strong and diffuse positivity for intestinal differentiation markers (CK20, CDX2) (Fig. 3A), and a focal expression of cervical differentiation markers (p16, CEA and CK7) (Figure 3B). No staining was obtained for PSA, ERs, PgRs and p63. Superficial growth pattern of the lesion, the identification of an adenomatous component area with high-grade dysplasia and the abrupt transition of tumor into normal-appearing vaginal squamous mucosa (Fig. 1A) were all features which supported the diagnosis of “*vaginal intestinal-type adenocarcinoma*”. An accurate clinical examination, vaginal ecography, colonoscopy and chest CT were also performed to exclude an intestinal-type adenocarcinoma from adjacent anatomic site and/or metastases. No neoplastic lesion was identified. Morphologic, along with clinical and radiologic features, were consistent with the vaginal origin of the tumor. The patient is currently disease-free after a 6-month follow-up.

Fig. 2. In the context of the adenocarcinoma, a small area with the characteristic features of a villous adenoma with high-grade dysplasia can be recognized. (H&E staining; original magnification 100x).



In order to compare molecular profile of this tumor with intestinal-type colorectal adenocarcinomas and provide major prognostic elements for potential biologic therapy options to clinicians, KRAS and NRAS expressions were analyzed by Polymerase Chain Reaction (PCR) and Pyrosequencing, but no over-expression of both genes was detected.

Fig. 1. A) Low magnification showing a polypoid lesion arising in the vagina; stratified squamous non-keratinized epithelium of vaginal mucosa can be seen at the lateral borders (H&E staining; original magnification 25x). B) At higher magnification, tumor consists of a moderately differentiated (G2) adenocarcinoma of the intestinal-type; goblet cells are evident. (H&E staining; original magnification 200x).

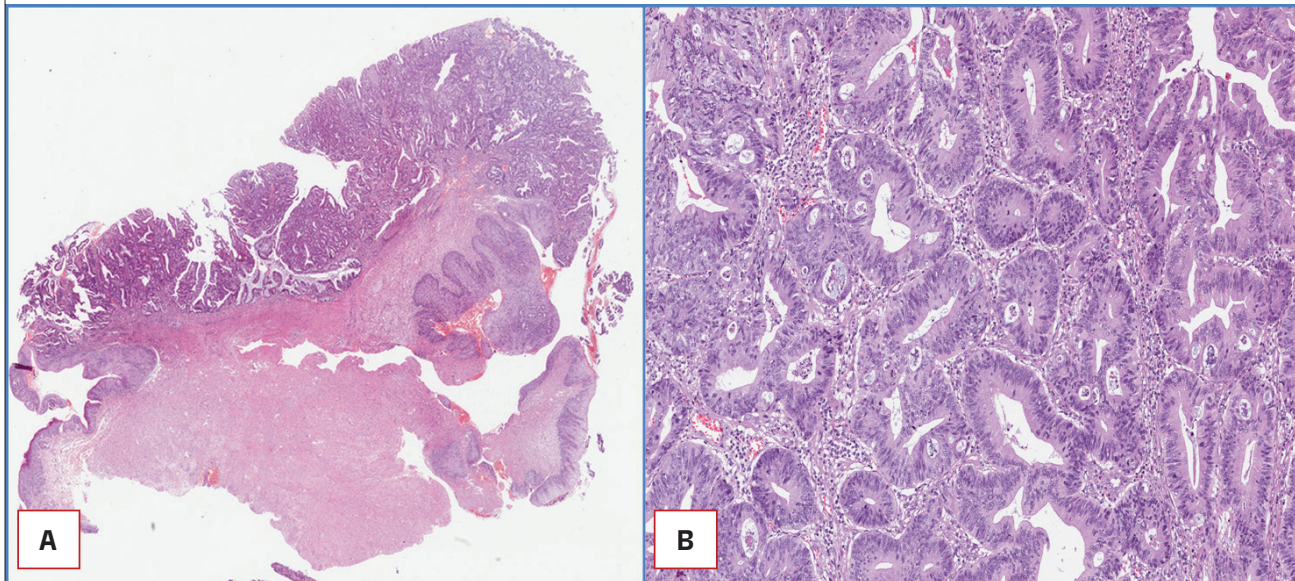
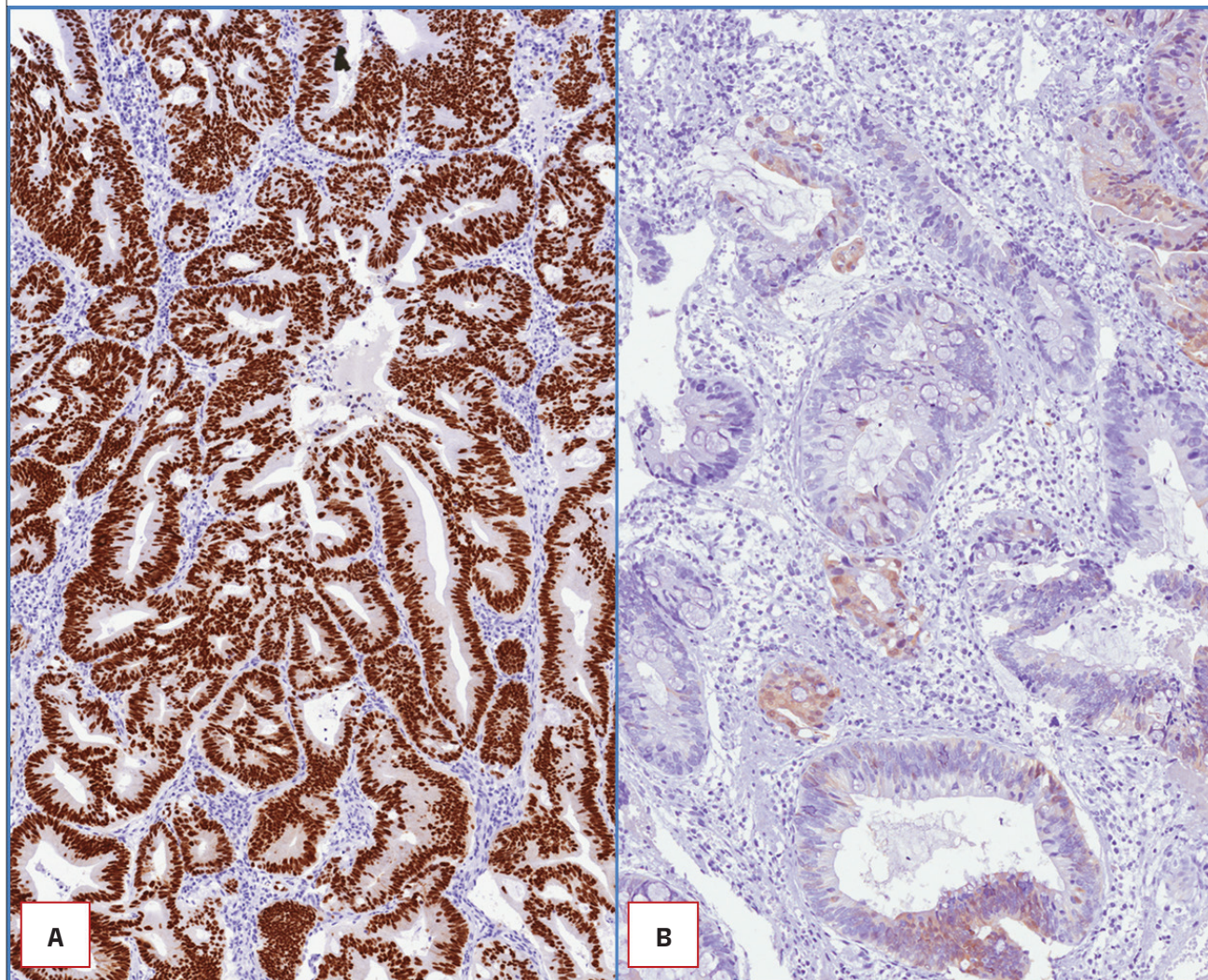


Fig. 3. Strong and diffuse positivity for CDX2 (A) and focal expression of p16 (B). (Immunoperoxidase staining; original magnification 200x).



Discussion

Vaginal adenocarcinoma is a very rare entity. Clinically two groups of vaginal adenocarcinoma can be distinguished: those associated with exposure to Diethylstilbestrol (DES) during pregnancy and those not DES-associated. The former generally arise in women younger than 40 and histologically are clear cell adenocarcinomas, while the latter affect women in peri- or post-menopausal age and are more frequently endometrioid, mucinous or intestinal-type adenocarcinomas⁸. The origin of adenocarcinomas in vagina is still matter of debate. It has been speculated that they may arise from foci of intestinal metaplasia from areas of adenosis⁹, or from heterotopic intestinal tissue, or from endometriosis or cloacal vestigia which should correspond to intestinal epithelium incorporated into the posterior vaginal wall during the division process of the cloaca. Despite the tissue of origin, the vaginal acidic environment could play a crucial role in the adenomatous transformation of the intestinal epithelium and the subsequent progression

through dysplasia into adenocarcinoma^{2,5}. To the best of our knowledge, only 19 cases of primary intestinal-type adenocarcinoma of vagina are reported in literature. The main clinico-pathologic features are summarized in Table I. Although a pre-existent non-neoplastic component was evident in almost all of the previously reported cases (18/19), a neoplastic adenomatous precursor was observed only in 8 cases.

The recognition of an adenomatous component in the context of an intestinal-type adenocarcinoma of vagina, as in our case, is consistent with the origin from vagina and argues against a metastatic lesion. With regard to histogenesis, the presence of a high-grade adenomatous component should favor an origin from cloacal remnants located in the posterior vaginal wall.

Immunohistochemically, intestinal markers (CK20 and CDX2) and CEA were strongly positive in 17 of 19 cases. CK7 expression was variable, whereas ERs and PgRs were constantly negative in all cases. Given the immunohistochemical overlap, metastasis from a cervix or colon adenocarcinoma should always be excluded be-

Tab. I. Pathologic features of intestinal-type adenocarcinomas of vagina reported in the literature.

Authors	Diagnosis	Associated lesions	Immunohistochemical features
Fox et al. (1988)	Adenocarcinoma, grade 1	Non-neoplastic intestinal epithelium	Unknown
Yaghsejian et al. (1992)	Adenocarcinoma, not graded	Non-neoplastic intestinal epithelium	Unknown
Heller et al. - case 1 (2000)	Adenocarcinoma, grade 1	Urethrovaginal fistula	CEA+
Heller et al. - case 2 (2000)	Adenocarcinoma, grade 1	Sinus tract to urethra	CEA+
Mudhar et al. (2001)	Adenocarcinoma, grade 2	Adenoma	CK20+, CEA+, CK7-
Tjalma and Colpaert (2006)	Adenocarcinoma, not graded	Tubulo-villous adenoma	CK20+, CEA+, CK7+, ER-, PgR-
Driss et al. (2007)	Adenocarcinoma, grade 2	Adenoma	CK20+, CEA+, CK7-
Ditto et al. (2007)	Adenocarcinoma, grade 3	None	CK20+, CDX2+, CK7-
van Wessel et al. (2013)	Adenocarcinoma, not graded	Tubulo-villous adenoma	CK20+, CEA+, CK7+, ER-, PgR-
Staats et al. - 10 cases (2014)	Adenocarcinomas, grade 1 (4/10), grade 2 (4/10), grade 3 (2/10)	Tubulo-villous adenomas (6/10); non-neoplastic intestinal epithelium (1/10); urothelium-lined ductal structures (3/10)	CK20+, CDX2+, CEA +, CK7 variable, ER-, PgR-
Present case (2017)	Adenocarcinoma, grade 2	Tubulo-villous adenoma	CK20+, CDX2+, CEA+, CK7 focally +, ER-, PgR-

fore making a final diagnosis of “vaginal intestinal-type adenocarcinoma”¹⁰.

Accordingly a careful evaluation of clinical and radiological features are mandatory to rule out a metastatic lesion^{2,4,11}.

The prognosis of vaginal intestinal-type adenocarcinoma mainly depends on the patient age (older individuals have generally a worse prognosis than younger), tumor stage, and differentiation. Regional lymph nodes status and distant metastasis may adversely affect prognosis. After making diagnosis and staging (based on FIGO and TNM classifications) tumor, several therapeutic strategies, depending on the stage, can be adopted. Surgical excision is the best treatment option, especially if a radical excision, as in our case, is feasible. A combination of radiotherapy and chemotherapy can be considered to reduce the tumor mass or as adjuvant therapy in advanced stage tumors.

Awareness by pathologists that an intestinal-type adenocarcinoma can occasionally arise from vagina is crucial to avoid a misdiagnosis of metastasis. As morphologic and immunohistochemical profiles between primary and metastatic tumors are similar, clinical and radiologic features are mandatory for a correct final diagnosis. The identification of an adenomatous component is helpful in supporting the origin from vagina.

References

¹ Ng QJ, Namuduri RP, Yam KL, et al. *Vaginal metastasis presenting as postmenopausal bleeding*. Singapore Med J 2015;56:e134-6.

² Tjalma WA, Colpaert CG. *Primary vaginal adenocarcinoma of intestinal type arising from a tubulovillous adenoma*. Int J Gynecol Cancer 2006;16:1461-5.

³ Ditto A, Martinelli F, Carcangiu ML, et al. *Incidental diagnosis of primary vaginal adenocarcinoma of intestinal type: a case report and review of the literature*. Int J Gynecol Pathol 2007;26:490-3.

⁴ Van Wessel S, Van Kerrebroeck H, Van Bogaert V, et al. *Primary intestinal type adenocarcinoma of the female genital tract, arisen from a tubulo-villous adenoma: case report*. Gynecol Oncol Case Rep 2013;4:63-5.

⁵ Staats PN, McCluggage WG, Clement PB, et al. *Primary intestinal-type glandular lesions of the vagina: clinical, pathologic, and immunohistochemical features of 14 cases ranging from benign polyp to adenoma to adenocarcinoma*. Am J Surg Pathol 2014; 38:593-603.

⁶ Matsuzaki A, Saio M, Kosuge N, et al. *Primary villoglandular mucinous adenocarcinoma of the vulva*. Case Rep Pathol 2017;2017:1765460.

⁷ Van Wessel S, Van Kerrebroeck H, Van Bogaert V, et al. *Primary intestinal type adenocarcinoma of the female genital tract, arisen from a tubulo-villous adenoma: case report*. Gynecol Oncol Case Rep 2013;4:63-5.

⁸ Tjalma WA, Monaghan JM, de Barros Lopes A, et al. *The role of surgery in invasive squamous carcinoma of the vagina*. Gynecol Oncol 2001;81:360-5.

⁹ Yaghsejian H, Palazzo JP, Finkel GC, et al. *Primary vaginal adenocarcinoma of the intestinal type associated with adenosis*. Gynecol Oncol 1992;45:62-5.

¹⁰ Ng HJ, Aly EH. *Vaginal metastases from colorectal cancer*. Int J Surg 2013;11:1048-55.

¹¹ Gardner CS, Sunil J, Klopp AH, et al. *Primary vaginal cancer: role of MRI in diagnosis, staging and treatment*. Br J Radiol 2015;88:20150033.